Periapical disorder

Acute periapical periodontitis

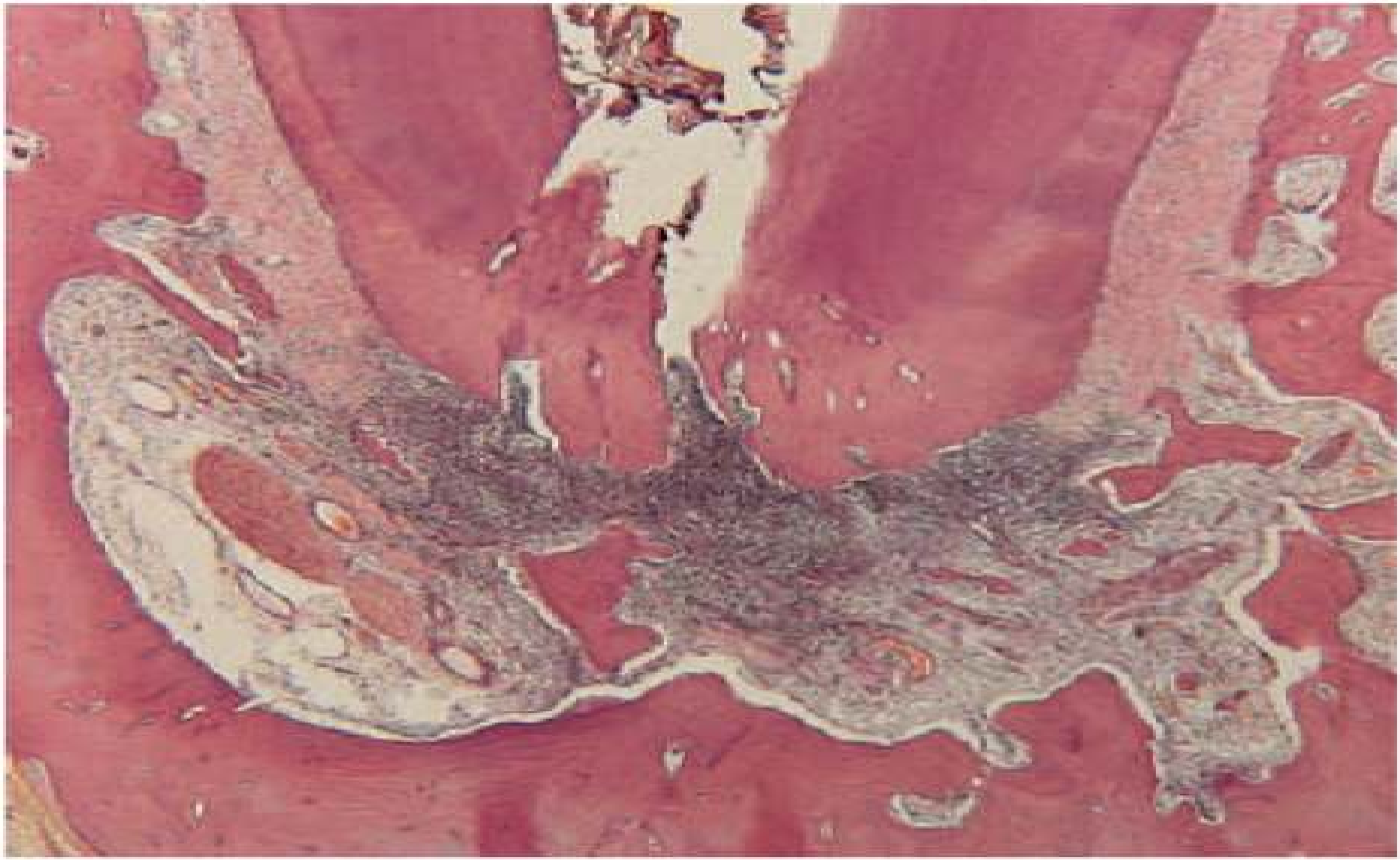

Fig. 4.17 Acute apical periodontitis. In this early acute lesion, inflammatory cells, mainly neutrophil polymorphonuclear leucocytes, are seen clustered around the apex of a non-vital tooth. The inflammatory cells are spreading around and into bone and there has not yet been time for significant bone resorption to develop.

PERIAPICAL GRANULOMA (CHRONIC APICAL PERIODONTITIS)

Periapical granulomas. Discrete periapical radiolucencies associated with the apices of the mandibular first molar.

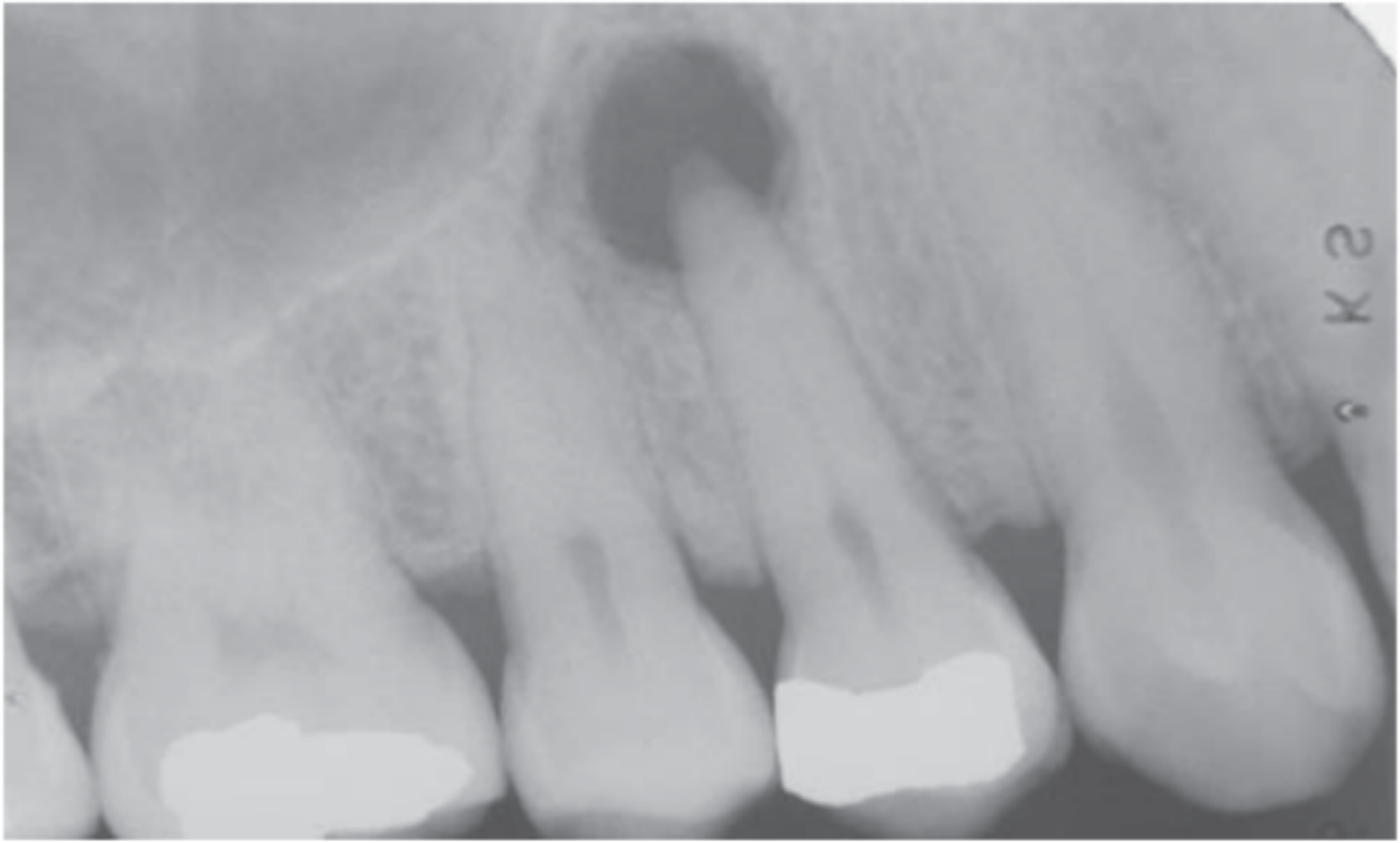

Fig. 3-15 Periapical granuloma. Well-defined radiolucency associated with the apex of the maxillary first bicuspid.

Fig. 3-16 Periapical granuloma. Large, well-defined radiolucency associated with the apices of the mandibular first molar. *(Courtesy of Dr. Robert E. Loy.)*

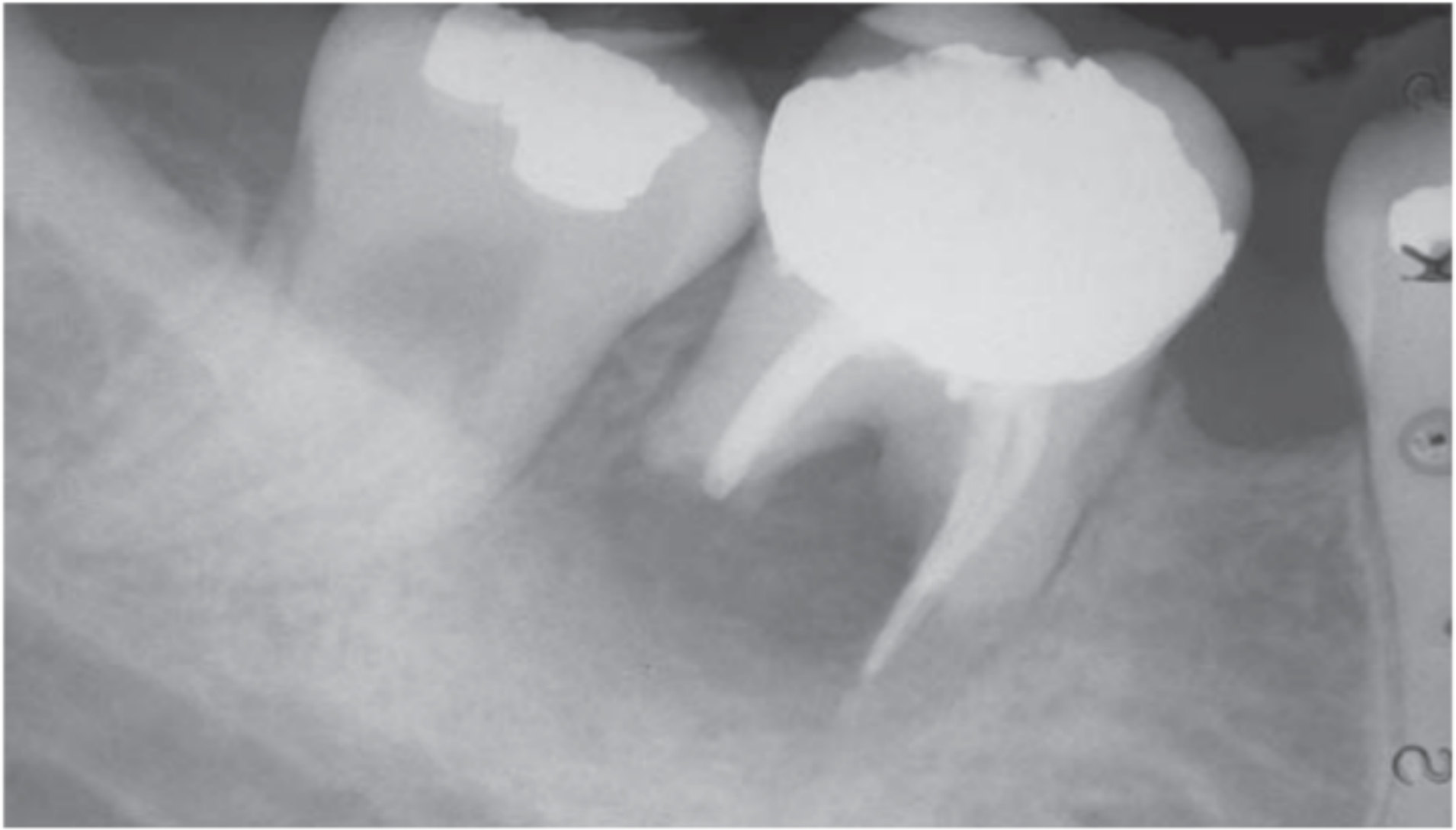

Fig. 3-17 Periapical granuloma. Ill-defined radiolucency associated with the mandibular first molar, which exhibits significant root resorption.

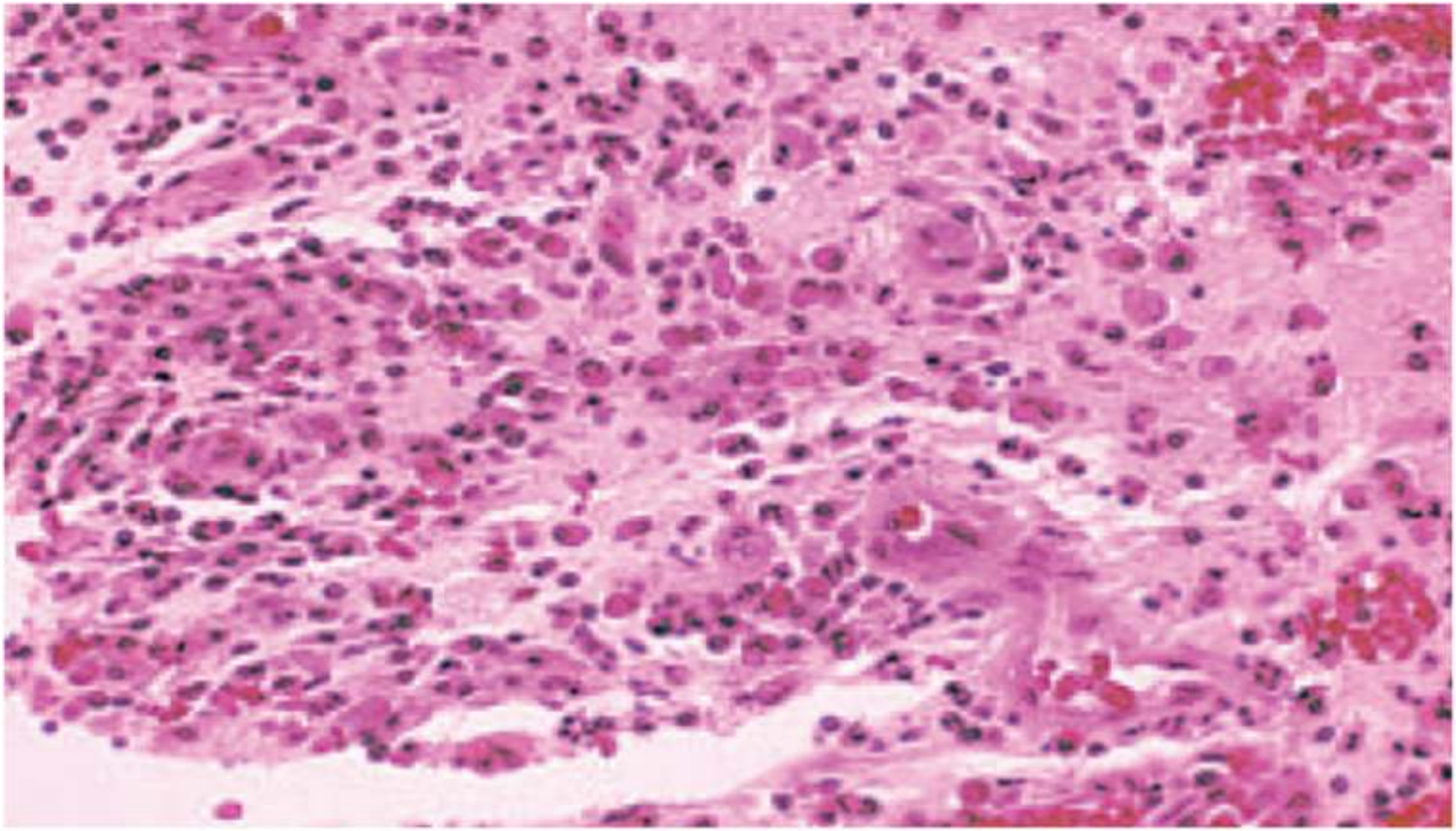

Fig. 3-18 Periapical granuloma. Granulation tissue exhibits mixed inflammatory infiltrate consisting of lymphocytes, plasma cells, and histiocytes.

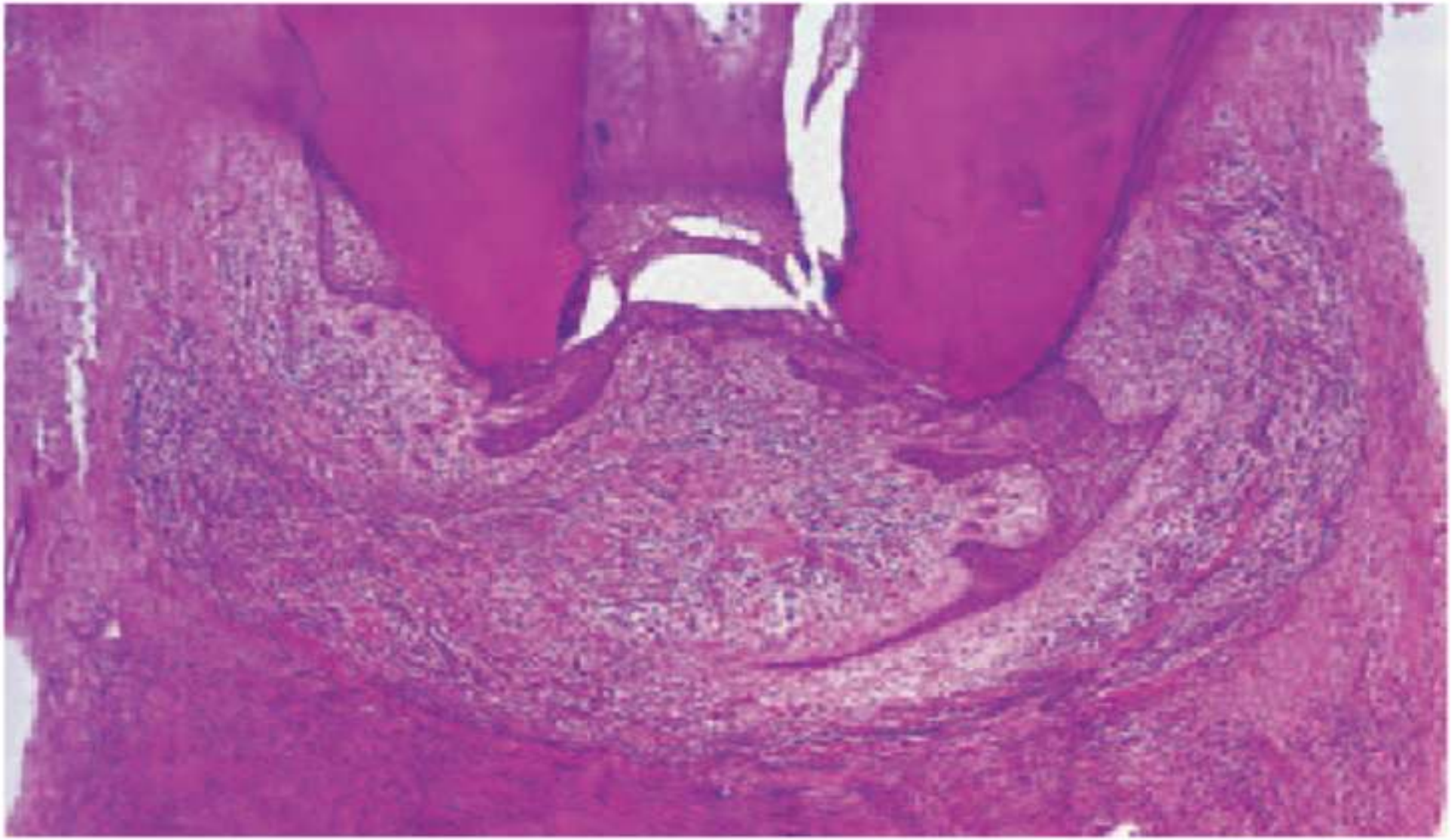

Fig. 4.22 Epithelial proliferation in an apical granuloma. Inflammation induces proliferation of odontogenic epithelium in rests of Malassez. This change may lead to cyst formation (Ch. 7).

Periapical cyst

Periapical cyst



1

Lateral Radicular cyst

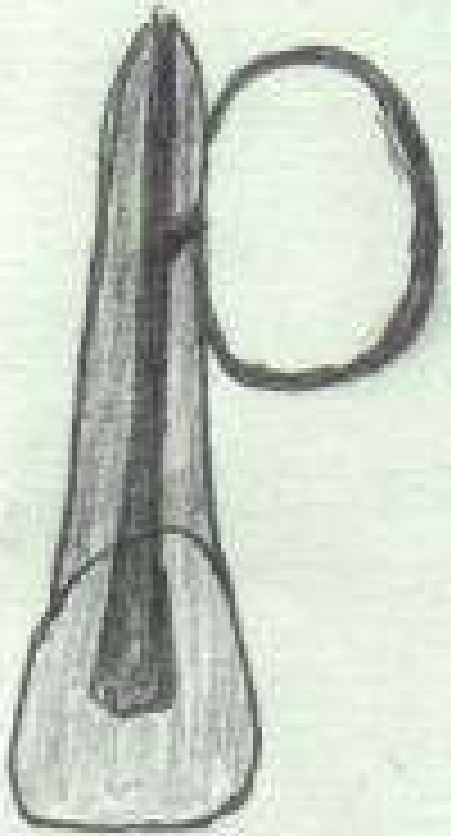

2

Residual cyst

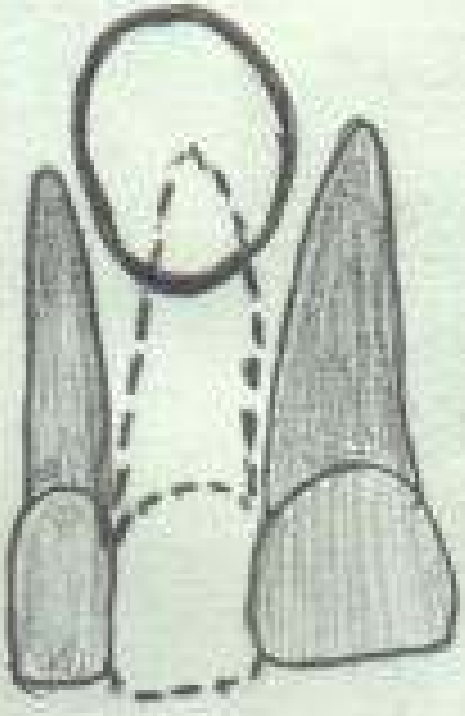

3

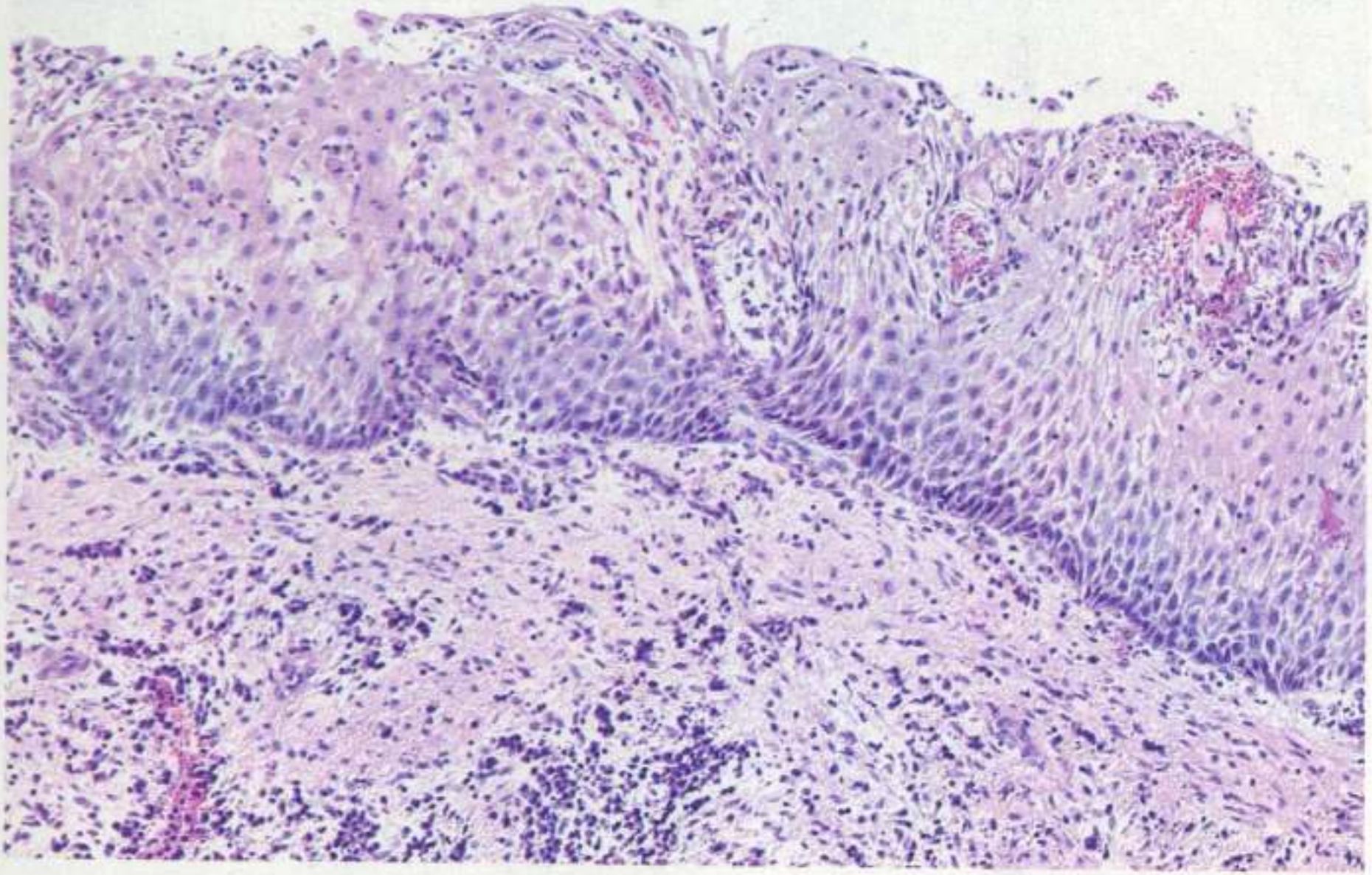

Fig. 127. Radicular cyst x 90

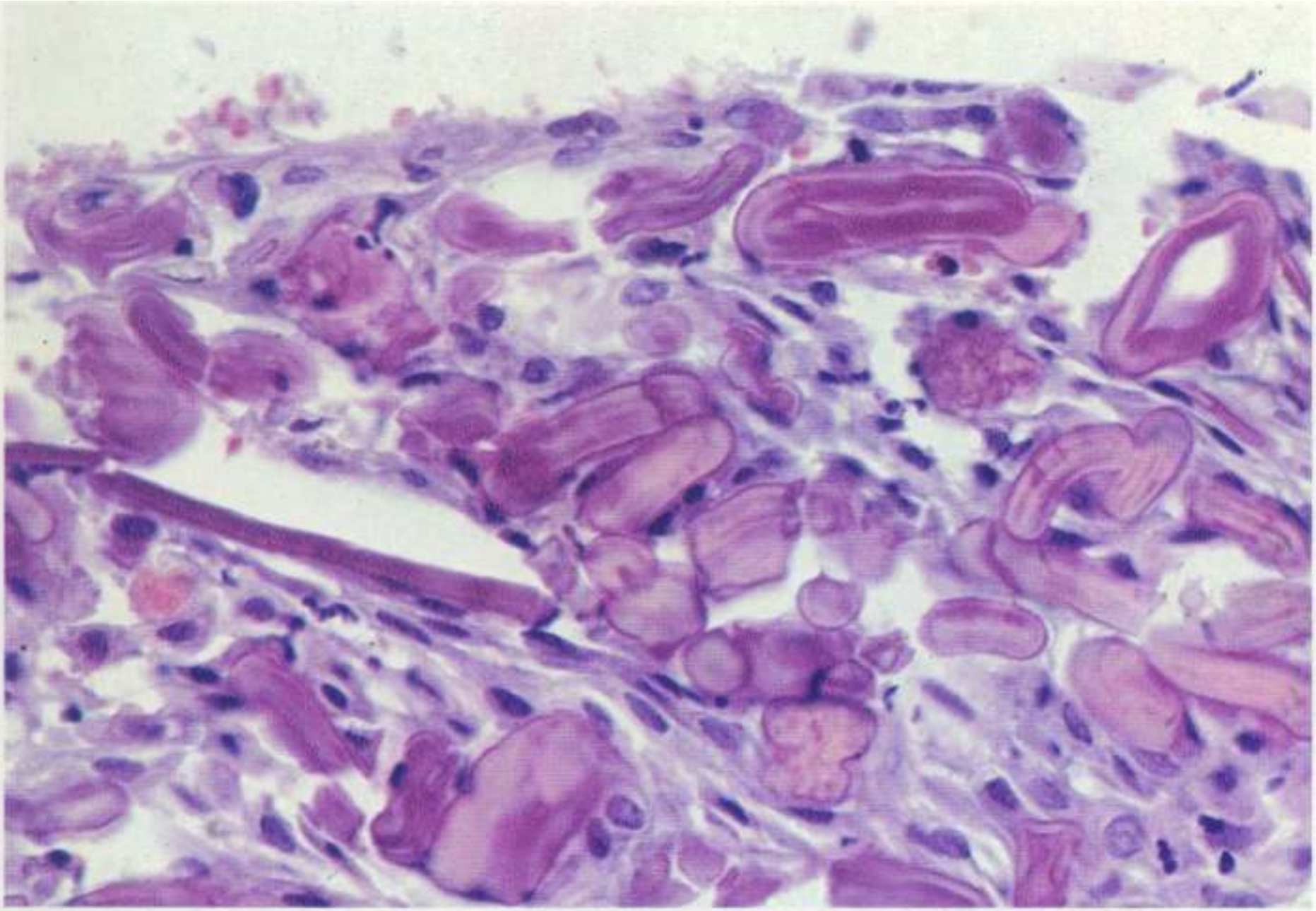

Fig. 131. Radicular cyst. Double-contoured hyaline bodies x 400

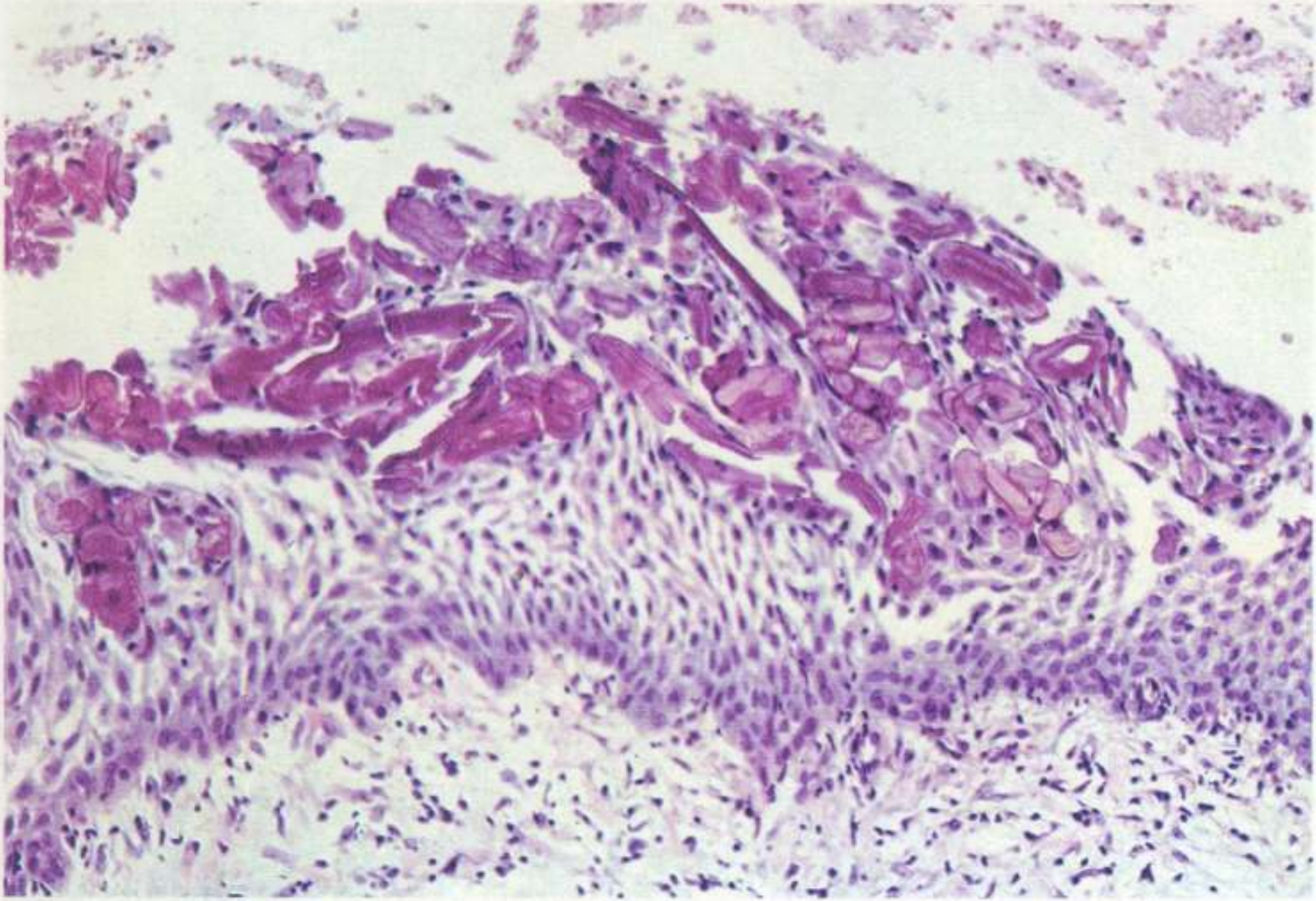

Fig. 130. Radicular cyst. Hyaline bodies in epithelium x 140

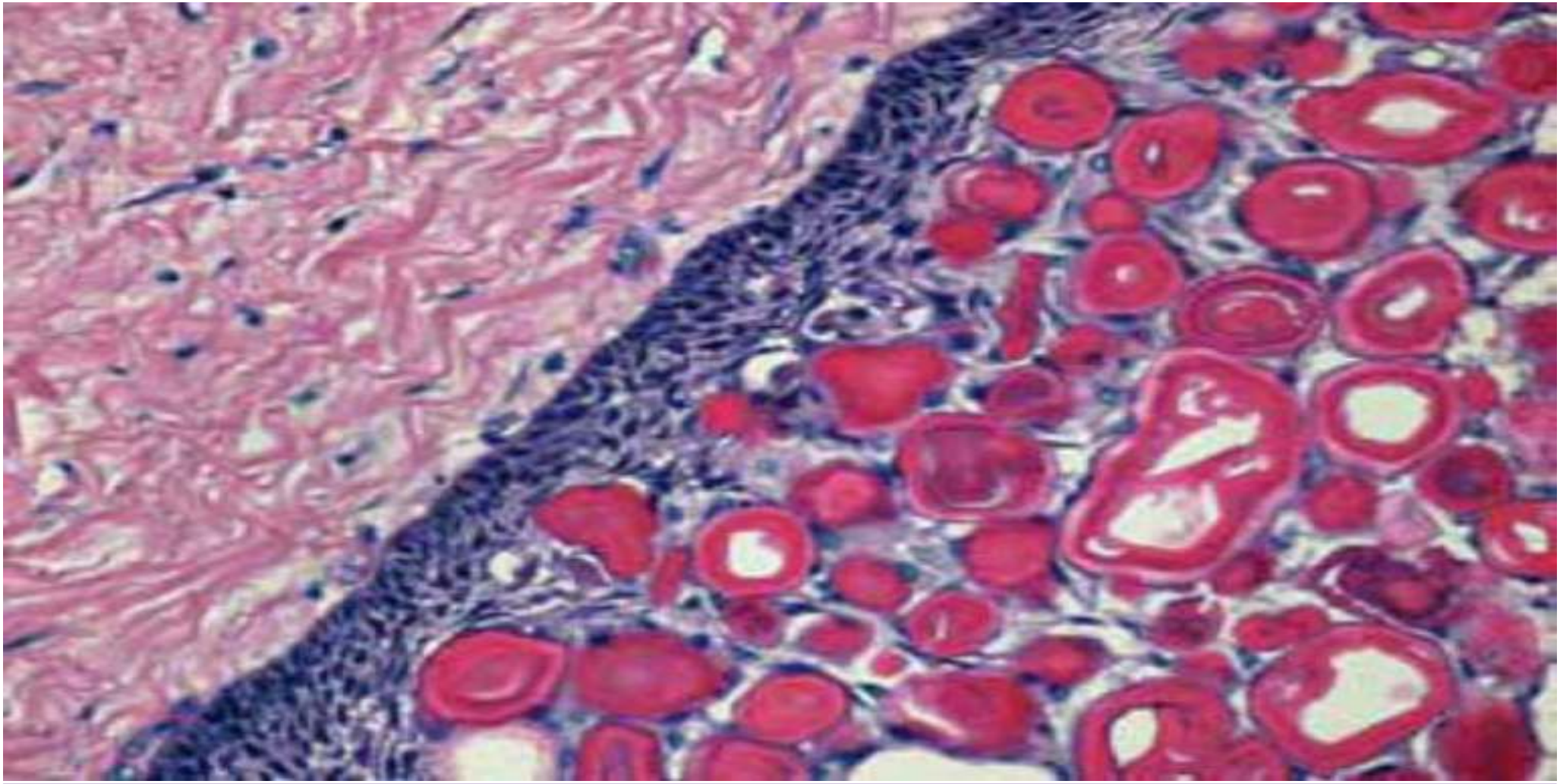

Radicular cyst. brightly eosinophilic Rushton bodies occur almost exclusively within the epithelial lining of cysts.

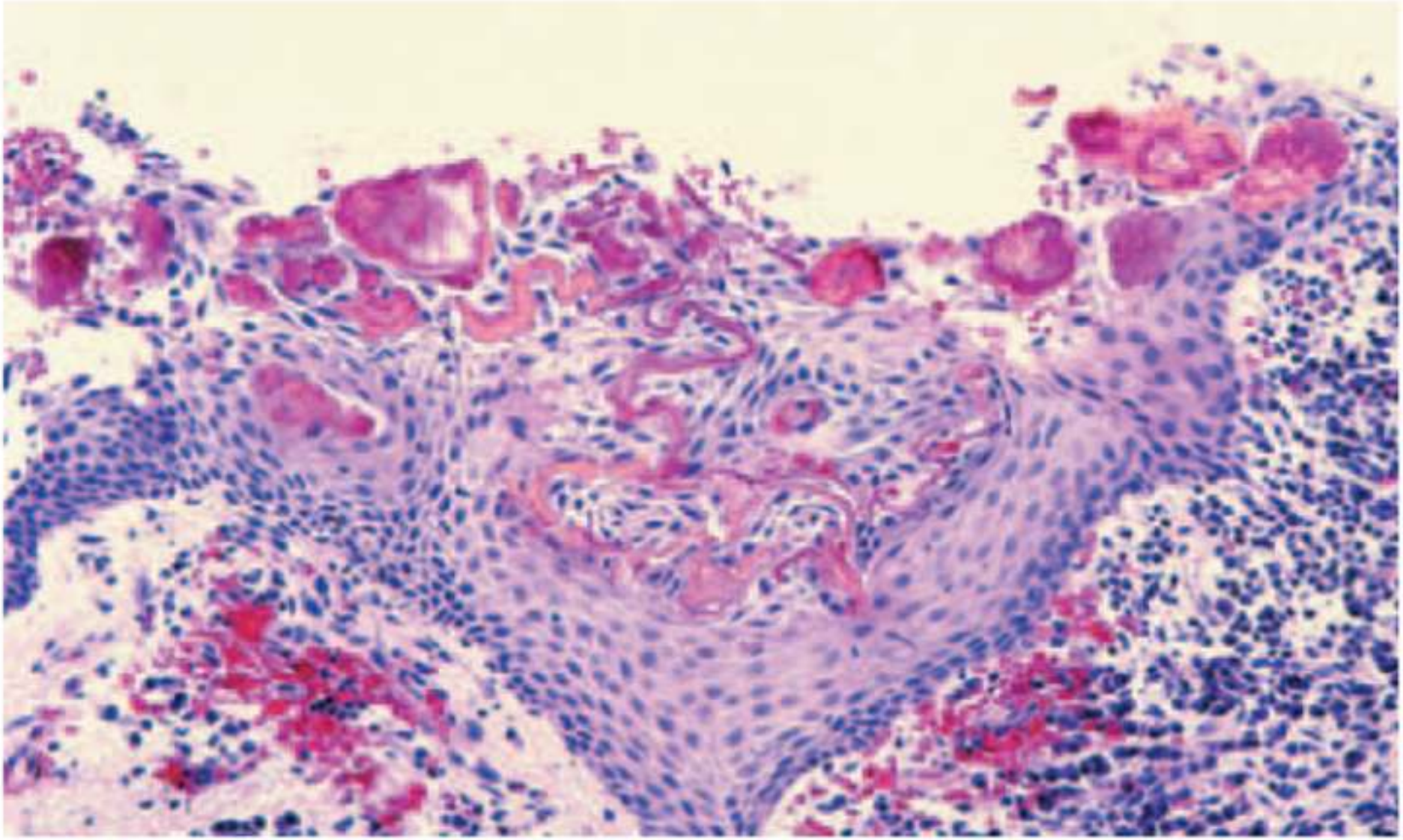

Fig. 3-32 Periapical cyst. Squamous epithelial cyst lining exhibiting numerous irregular and curvilinear Rushton bodies.

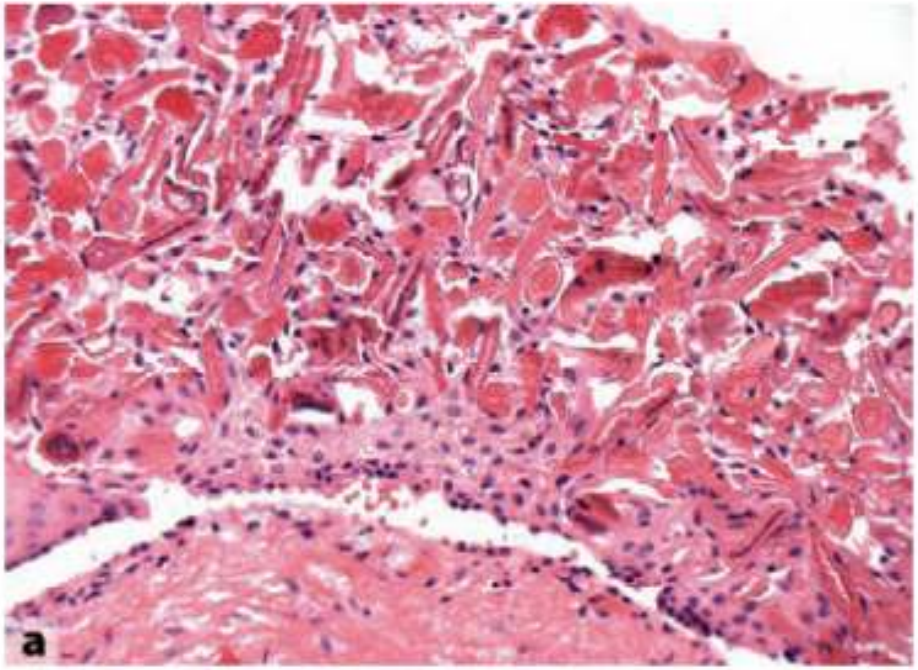

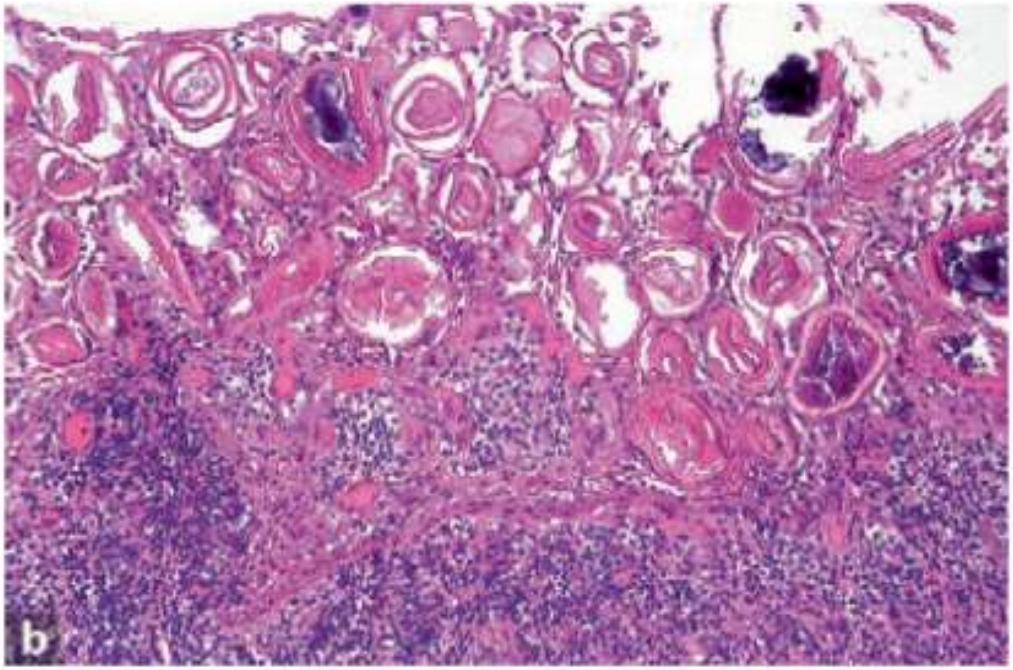

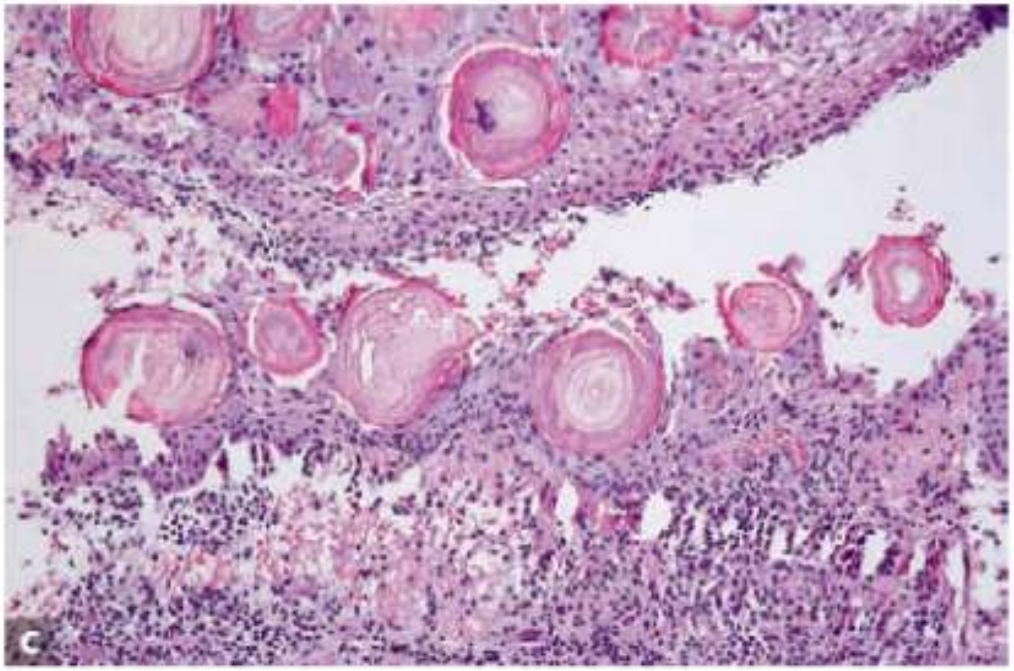

Fig. 9.4a–c Various appearances of Rushton bodies in epithelial lining of radicular cysts. **a** Rod-like, **b**, **c** More or less organised concentrically lamellated bodies

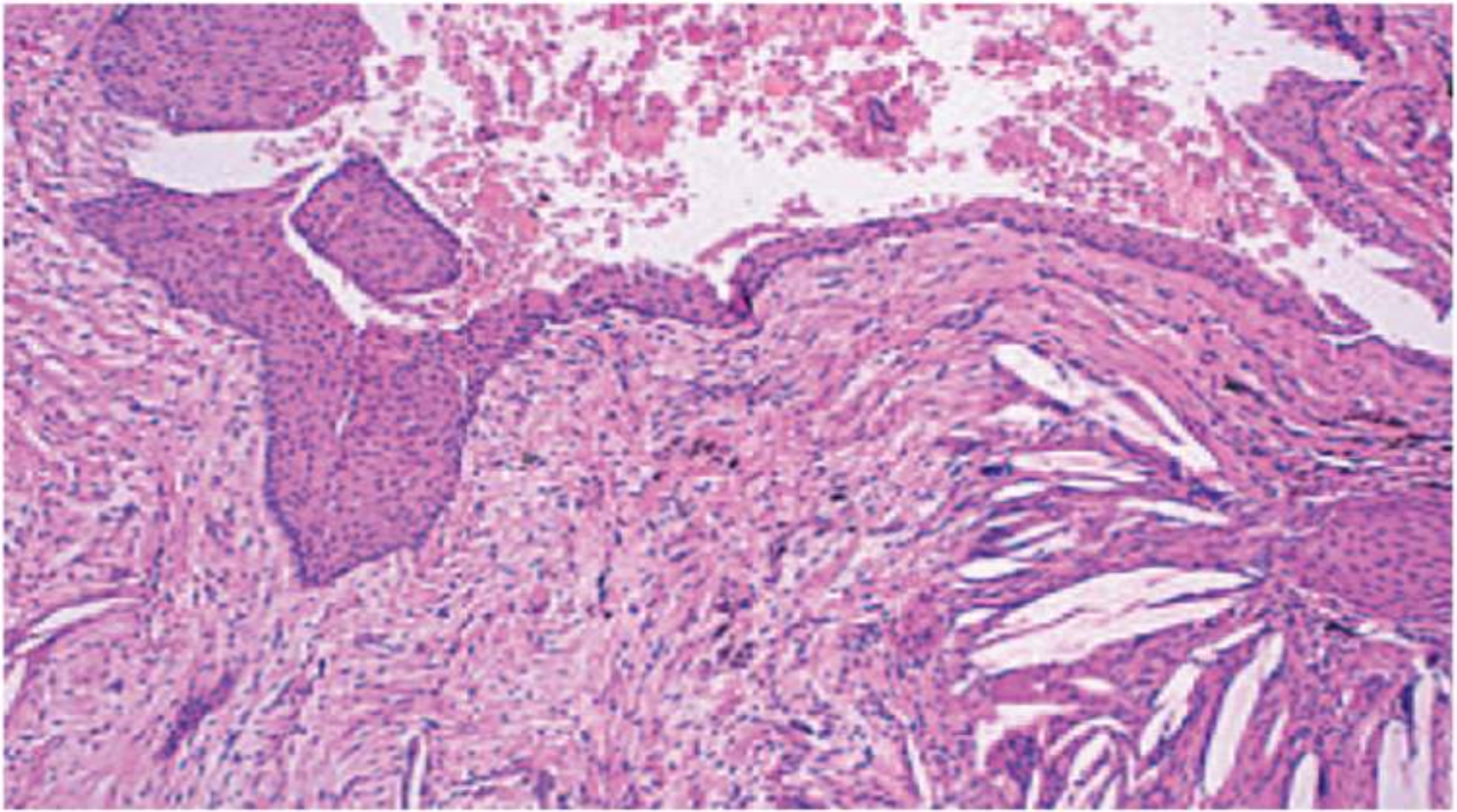

Fig. 3-30 Periapical cyst. Cyst lined by stratified squamous epithelium. Note connective tissue wall, which contains a chronic inflammatory infiltrate and numerous cholesterol clefts.

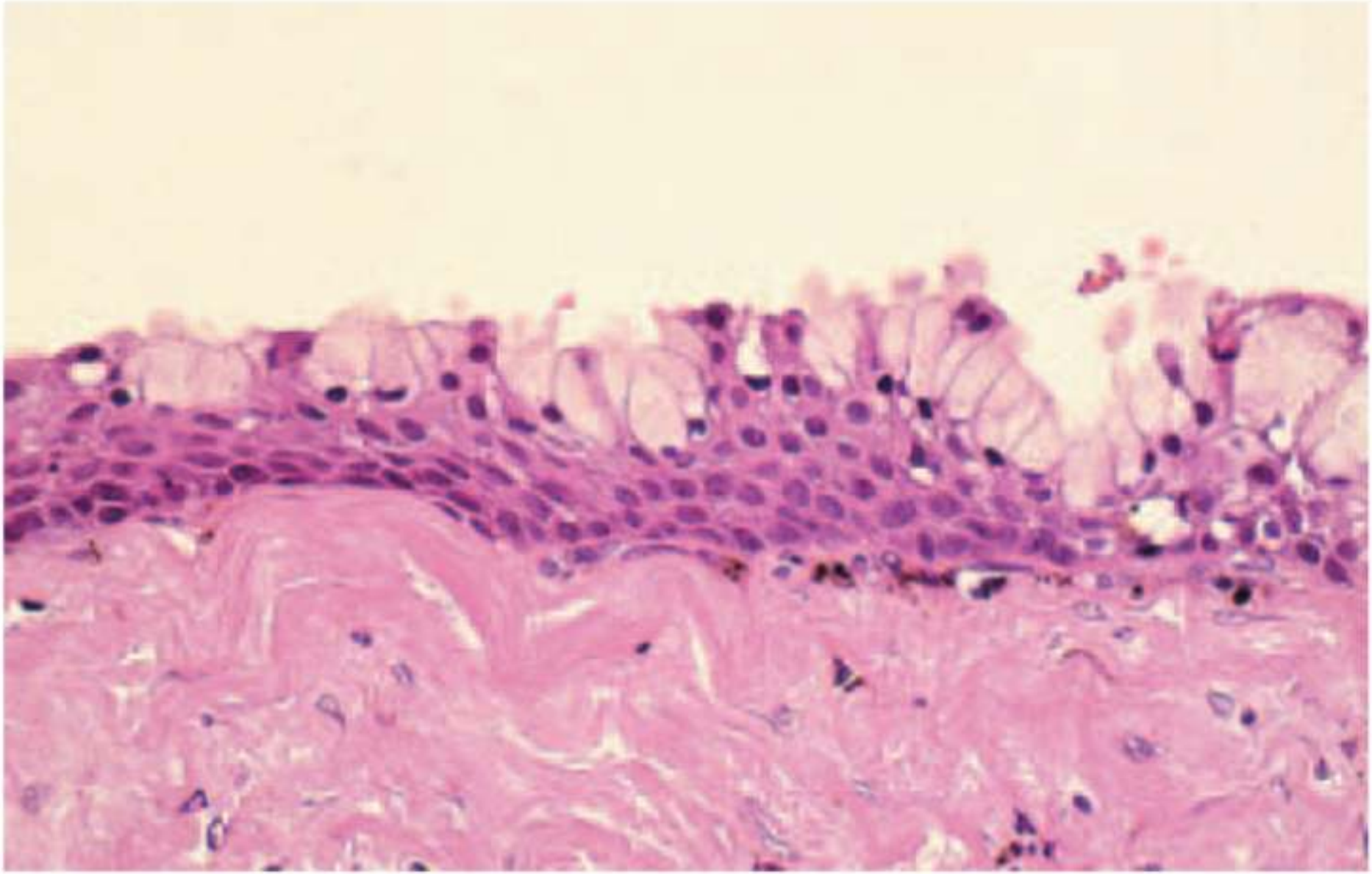

Fig. 3-31 Periapical cyst. Stratified squamous epithelial lining containing numerous mucous cells.

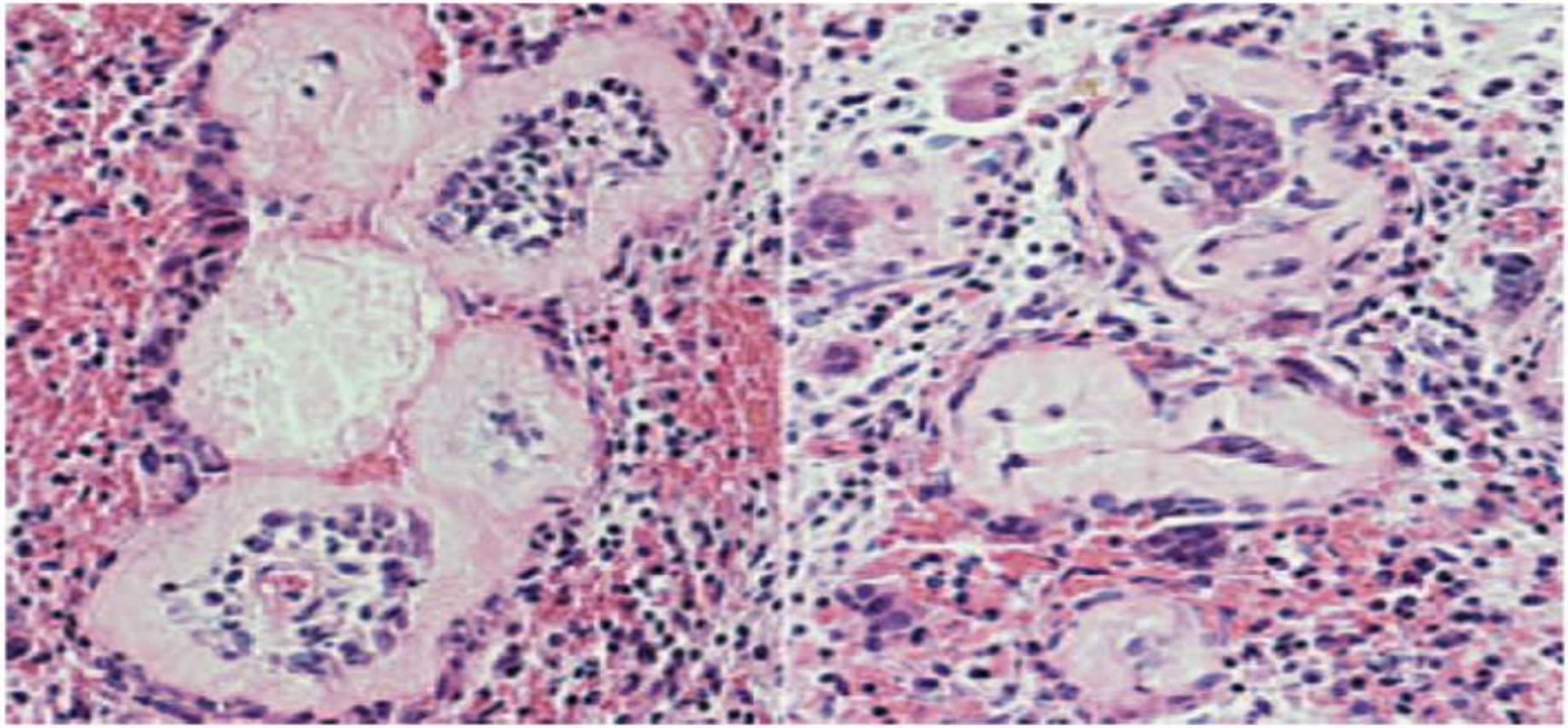

Fig. 3-33 Hyaline bodies. A, Multiple hyaline bodies appearing as corrugated collagenous rings surrounding lymphocytes and plasma cells; note early hyaline body filled with serum. **B,** Multiple hyaline bodies with numerous multinucleated giant cells within and around the corrugated collagenous rings.

Periapical abscess

Fig. 3-35 Periapical abscess. Same patient as depicted in Fig. 3-34. Multiple, overlapping radiolucencies of the anterior maxilla are present. All four maxillary incisors exhibit pulpal necrosis.

Fig. 3-41 Periapical abscess. Same patient as depicted in Fig. 3-40. Periapical radiolucency associated with the nonvital mandibular lateral incisor.

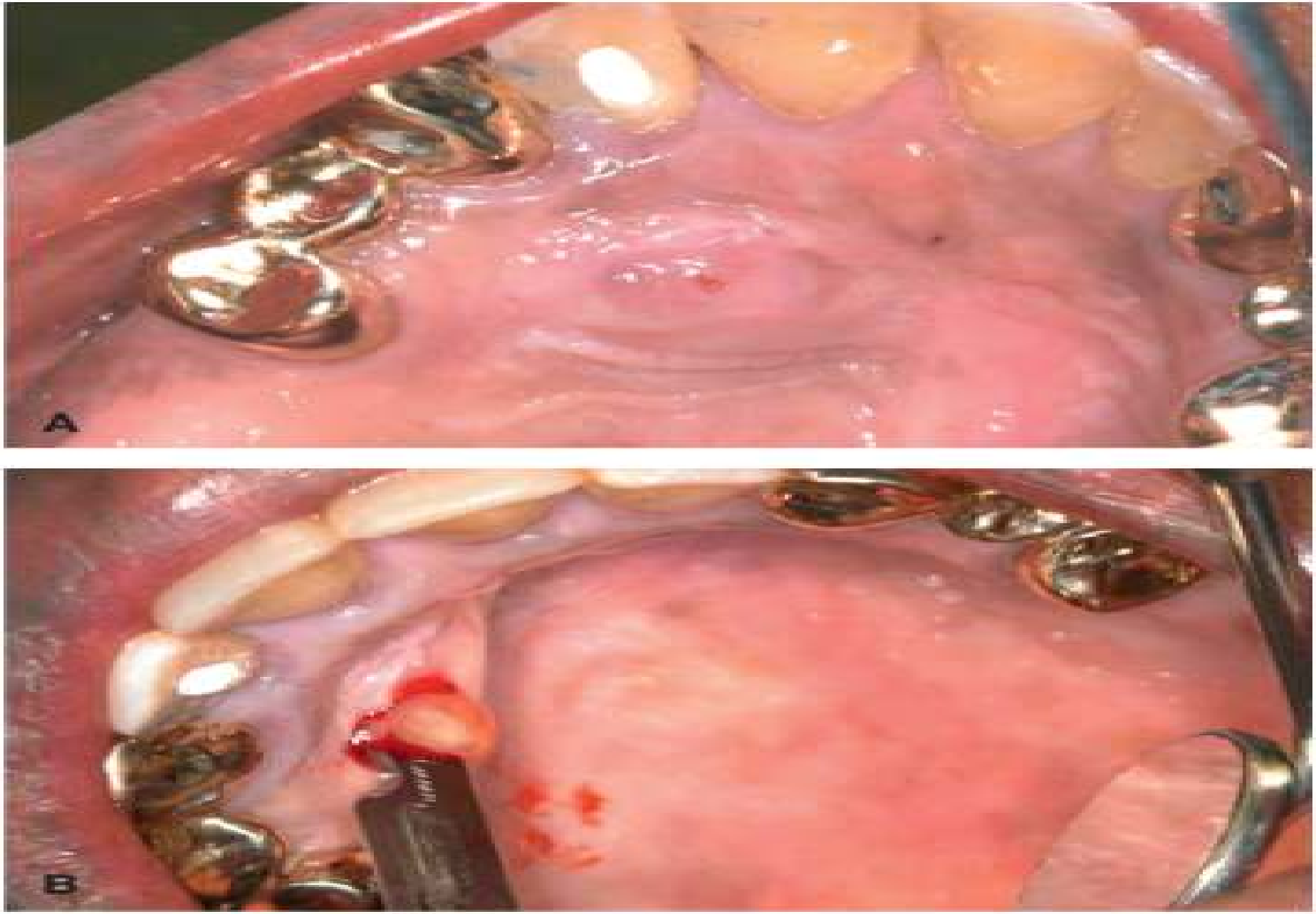

Figure 2–55 **Apical abscess. A.** Drainage channel (sinus tract). **B.** Incision performed to allow purulent material to drain.

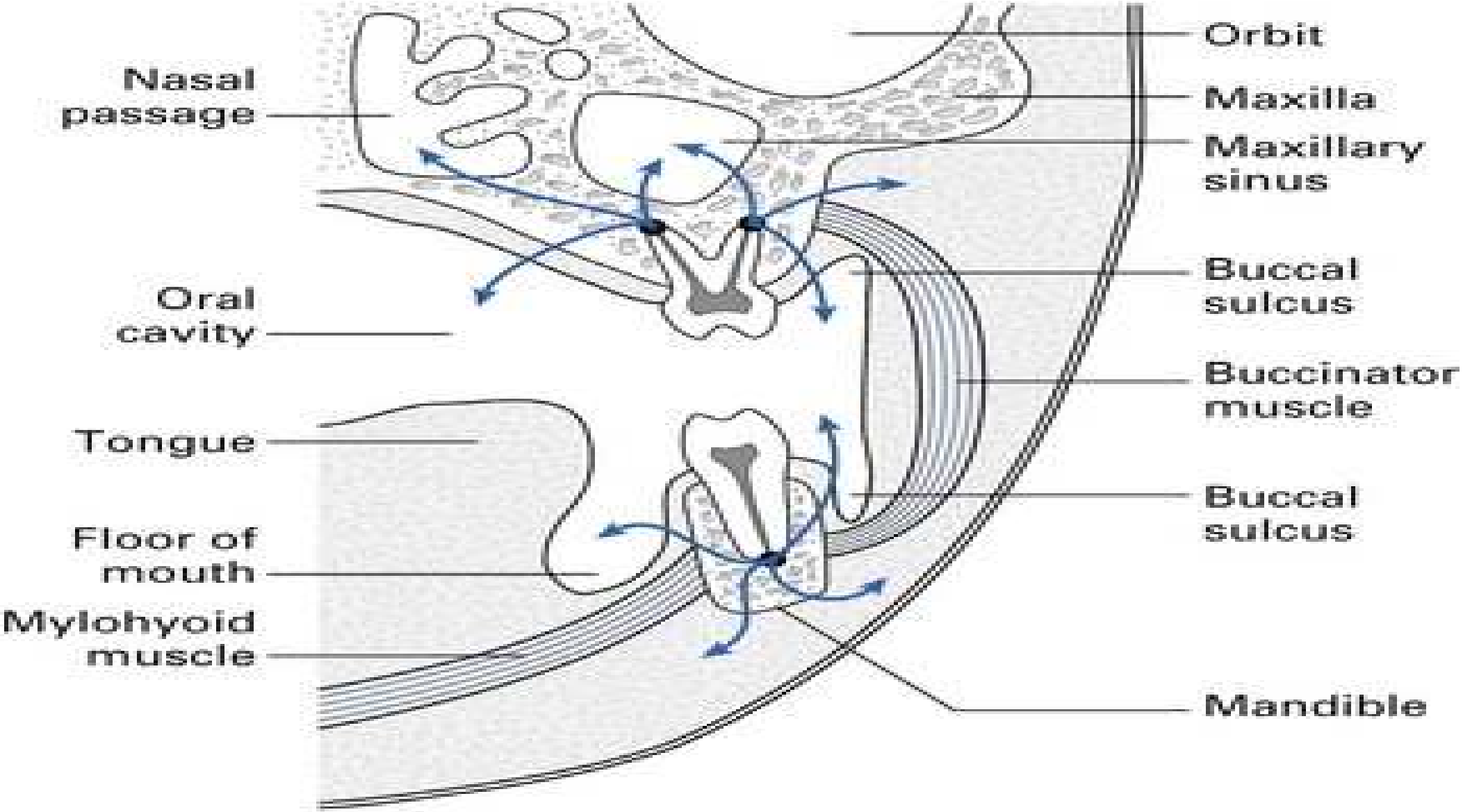

Routes of abscess escape related to posterior (mandibular and maxillary molar and premolars)

Fig. 3-43 Ludwig's angina. Soft tissue swelling of the right submandibular region. *(Courtesy of Dr. Brian Blocher.)*

Ludwig's Angina

- Rapid swelling cellulitis of sublingual & submaxillary spaces
- Dental infection, floor of mouth, salivary gland
- Fever, edema & erythema of neck under chin & floor of mouth